

## ORIGINAL ARTICLE

# Outcome of Single Dose Prophylactic Antibiotic in Carpal Tunnel Release Surgery

**Inayat Ali Khan**

*Department of Neurosurgery, Dammam Medical Complex, Dammam, Saudi Arabia.*

## ABSTRACT

**Background:** It has been well documented that administering a prophylactic antibiotic brings down the rate of postoperative wound infection very strikingly in carpal tunnel release (CTR) surgery. Carpal tunnel syndrome (CTS) is definitely a compressive neuropathy of the upper limbs, which is both benign and frequent. The study objective was to determine the postoperative wound infection rate in carpal tunnel release surgery after having administered a single dose of a prophylactic antibiotic.

**Methods:** This cross-sectional study was carried out at the department of Neurosurgery, Dammam Medical Complex-Saudi Arabia. The study was based on 122 patients who were operated for carpal tunnel release procedures at the centre. Pre-operatively all patients were subjected to nerve conduction studies (NCS) to document CTS as the definitive diagnosis. As a routine, every patient was administered intravenous loading dose of cefuroxime (1.5g) at least 1 hour prior to surgery. All patients were treated as day care cases and were discharged after a few hours of surgery. On discharge, no further antibiotics were administered. Their wounds were examined at three, ten and fourteen days. Suture removal was performed on the fourteenth postoperative day.

**Results:** Superficial redness over the site of incision was noted in three of the patients and wound infection in two others. These two patients improved with oral antibiotics. Not a single patient needed re-exploration.

**Conclusion:** The current study showed that this is an efficacious and a very safe protocol to follow. Assuming the fact that the incidence of surgical site infection (SSI) in CTR surgery is low, the results were not different when compared to the results from other centres.

**Keywords:** Prophylactic/Prophylaxis; Antibiotics; Carpal Tunnel Release Surgery; Infection; Carpal Tunnel Syndrome.

## Corresponding Author:

**Dr. Inayat Ali Khan**

Department of Neurosurgery,  
Dammam Medical Complex,  
Dammam, Saudi Arabia.  
Email: inayatbrain@yahoo.com  
doi.org/10.36283/PJMD9-2/004

## INTRODUCTION

Carpal Tunnel Syndrome (CTS) continues to present as a disabling condition, which is seen in 3.8% of the general population, and on the average around 20% of patients diagnosed with CTS undergo surgery<sup>1,2</sup>. It is the most frequently occurring form of entrapment of the median nerve and accounts for 90% of all entrapment neuropathies<sup>3</sup>. It results from a compressive neuropathy involving the median nerve as it travels through the wrist at the carpal tunnel<sup>4</sup>. The syndrome of median nerve entrapment is a mono-neuropathy that can result in altered

sensations in the hand while affecting motor function as well<sup>5</sup>. Being the commonest neuropathy of the upper limb at least one million, new cases are diagnosed each year in the United States<sup>2,6</sup>.

Pain being the main symptom, other common symptoms include numbness and tingling sensations in the middle and index finger and the thumb, as well as the lateral aspect (lateral half) of the ring finger<sup>5</sup>. Sleep disorders were also a frequently reported problem in some studies<sup>7</sup>. The options of nonsurgical treatments include physiotherapy, steroids<sup>8</sup> (per oral or locally injectable) and

splinting.<sup>9</sup> The American Academy of Orthopaedic Surgeons however prefers a trial of conservative (nonsurgical) therapy before considering surgical release<sup>10</sup>. When nonsurgical attempts to treat CTS fail, surgical decompression also known as carpal tunnel release (CTR) is indicated and this is in fact a transverse carpal ligament release.

Early surgery with CTR is preferred when there is clinical and investigative proof of denervation of the median nerve or a patient prefers to go ahead directly for the surgical option<sup>10</sup>. Success rate after CTR is now well-documented<sup>11</sup> as is the low complication rate<sup>12</sup>.

Ambiguity for preoperative antibiotic prophylaxis does persist in clean soft tissue procedures of the hand in which the rate of infection is still low<sup>13, 14</sup>. In particular, the prevalence and frequency of surgical site infection (SSI) has not been addressed in detail in the guidelines by Centre for Disease Control (CDC) and its subsequent relationship determination with preoperative prophylactic antibiotics as well<sup>15</sup>.

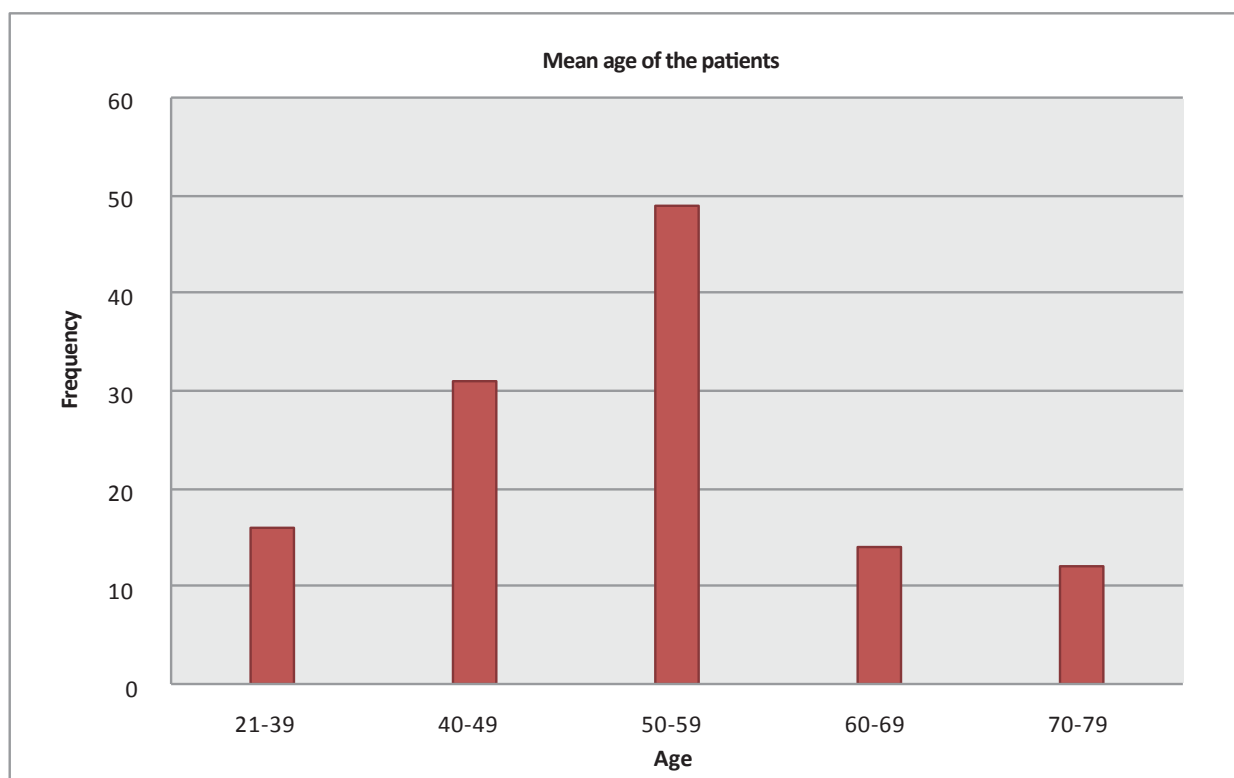
The objective of the study is to ascertain the safety and efficacy of single dose prophylactic antibiotics alone in CTR surgery. The role of single dose antibiotic prophylaxis has been studied in various parts of the globe but in Dammam, data on carpal tunnel surgery and the efficacy of single dose antibiotics is sparse. Hence, apparently there seemed a necessity to collect data on this topic

and simultaneously ensuring patient safety.

## METHODS

In the cross sectional study, the researcher reviewed the results of single dose antibiotic prophylaxis protocol in 122 consecutive patients of which 105 were females and 17 were males who underwent CTR surgery at the centre (Dammam Medical Complex, Saudi Arabia). The study was performed between September 1, 2013 and February 28, 2016 and it was also approved by the Ethical Board of Dammam Medical Complex. Further, SPSS was used to check the significance of the results with the reported studies of the past.

The noted mean age of the patients (Graph 1) at the time of admission was 56 years. The most patients – around 46% – were admitted for surgery from the age range 50-59 years, followed by 60-69 years (30%), 40-49 years (14%) and 70-79 years (just under 10%). All patients were screened for a 30-day period considering the fact that there is a high probability that infection can be seen within this given period for any soft tissue procedure such as a carpal tunnel release surgery. Additionally, 30 days is the given period employed to define a wound infection after a soft tissue procedure in which implants are not being used as recommended under the CDC guidelines<sup>15</sup>. Interestingly we also noted that many patients reported symptoms beyond the territory of the median nerve as well.



Graph 1: Mean age of the participants.

All 122 patients underwent nerve conduction studies (NCS) of both upper limbs to confirm the clinical diagnosis of CTS. NCS has been recommended by Stevens et al.<sup>16</sup> and labelled as the gold standard by Kasundra et al.<sup>17</sup>. Interestingly symptoms of CTS were reported more commonly in both the median and ulnar digits than in the median digits alone. Symptoms were also reported in areas other than the digits. Thus, 23% of patients had forearm paresthesias and pain; 14% reported elbow pain; 11% reported arm pain; 6.5% reported pain in the shoulder; and 2.45% reported neck pain, almost similar to what has been noted in literature review<sup>18,19</sup>.

All patients were operated as day care cases. Males and females of all age groups were included in this study. Although two common options available to the patients included the endoscopic approach and the open method, we only used the open method of CTR surgery at the centre. A detailed informed consent was obtained in the day care area where the patients initially reported for their surgery. All patients were mandated to take an early morning shower using any antimicrobial soap. All procedures were performed under local anaesthesia, with the patient lying in the supine position and the arm stretched out. No additional staffs were allowed in the operating room, as per ASHP (American Society of Health-system Pharmacists) recommendations<sup>20</sup>.

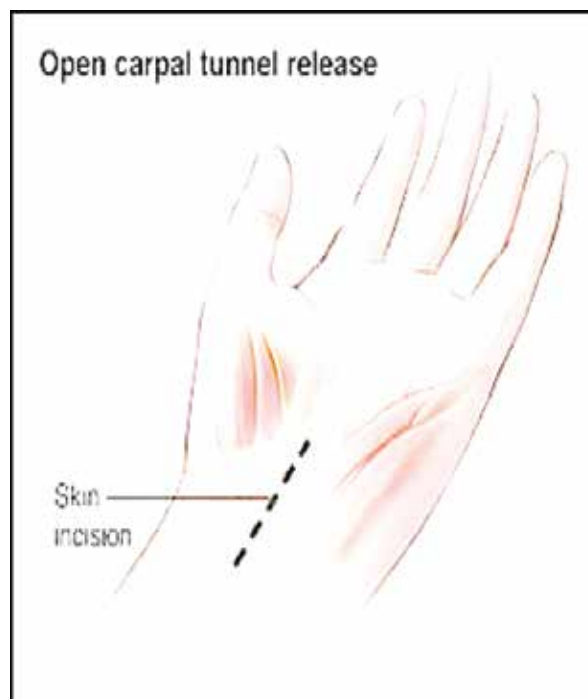
The choice of selecting an ideal antibiotic for prophylaxis in clean surgical cases must include the following considerations: relatively inexpensive, limited adverse effects, an acceptably long half-life in tissue and serum, optimal subcutaneous and muscular tissue penetration and should be adequately broad to be efficacious but confined to avoid resistance and superinfections<sup>21</sup>. Hence keeping the protocol of antimicrobial prophylaxis (for primary prophylaxis) of a single-dose therapy affront, a second-generation cephalosporin (Cefuroxime) was chosen for the study.

Preoperative antibiotics are given within thirty minutes to one hour before starting the surgical procedure and this has been the practice at several centres around the globe<sup>22</sup>. Interestingly, one study confirmed that in humans, antibiotics given 2 hours prior to the start of the surgical procedure had the best effect on scaling down the rate of surgical wound infections<sup>21</sup>. Hence, for all patients, injection cefuroxime 1.5 gram was given at least two hours before the start of the procedure.

After reaching the operating theatre, each patient was given a ten-minute betadine scrub. An alcohol scrub followed this and then dry gauze was applied. The surgeon and the scrub nurse used double gloves (and this has always been an inherent protocol for all procedures whether under local

or general anaesthesia).

The local anaesthetic agent used was Xylocaine 1% with adrenaline (1:200,000). Adrenaline was added as a vasoconstrictor to lessen the chances of bleeding during surgery. A palmar crease incision was used in all patients (Figure 1); and the incision never crossed the wrist flexion crease as recommended by Shapiro<sup>23</sup>. A two-inch incision was given and the transverse carpal ligament was brought into view and cut hence exposing the decompressed median nerve.



**Figure 1: Palmar crease incision (this is purely hand drawn).**

Bleeding was meticulously handled and at the end of the procedure the wound was generously irrigated first with hydrogen peroxide and then with saline containing Gentamicin. The skin was then sutured. After surgery, all patients were shifted to the ward (day care) and were monitored for a minimum of two hours after which they were discharged home. The wound was examined on the third, tenth and fourteenth day of surgery. The patients were followed for any evidence or suspicion of infection like wound redness and Edema, wound dehiscence, purulent or serous discharge from the wound, severe pain and fever.

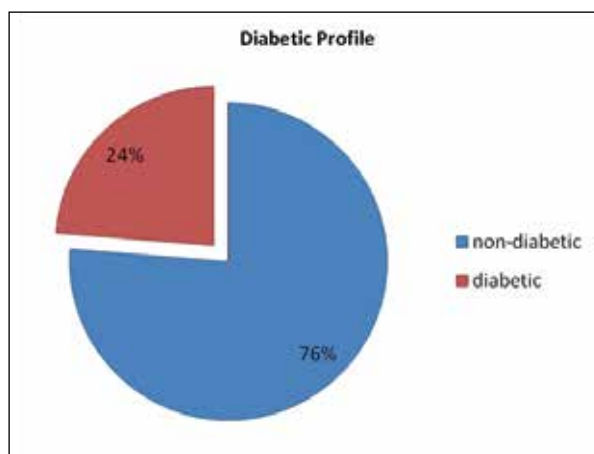
## RESULTS

This study was conducted at the department of neurosurgery, Dammam Medical Complex. A total of 122 patients were operated of which 105 were females. The prevalence of CTS in diabetic patients is well known<sup>24</sup> (Figure 2) while Table 1 represented the aspects of CTS in the study.

**Table 1: Parameters and co-morbidities specifically defined for the study.**

Variables	No. of Patients	p-Value
Total carpal tunnel releases	122	
Gender		p = 0.01
Males	17	
Females	105	
Co-morbidities		
Diabetes Mellitus		
Positive	24%	
Negative	76%	
Total	100%	

Less than 0.05 is significant

**Figure 2: Diabetic profile of the patients.**

Age related status reported that most patients in the age range of 50-59 years with CTS in the study were referred for surgery, hence accounting for 40% of the total patients, followed by 40-49 years (25%), 21-39 years (13%), 60-69 years (12%) and 70-79 years (10%). The mean age of all patients at the time of admission was 54 years (range 21-79). Symptoms at the time of presentation actually divided the patients into two major groups. The first group consisted of those patients -89 (73%) in whom the most prominent symptom to start with was numbness along the median nerve distribution followed by hand pain, weakness and decreased sensations. The second group consisted of those patients -33 (27%) who first experienced hand pain followed by numbness, weakness and decreased sensations. Still others had experienced a mixture of other symptoms like weakness, stiffness and hand swelling. Bilaterality and handedness indicated that most of the patients were right-handed -117 (96%), while 5 patients (4%) were left handed. At the time of presentation, 59 patients (48%) had right hand CTS, 28 patients (34%) had bilateral CTS and the remaining 22 patients (18%) had left hand CTS.

Rate of surgical site infection reported that Readmission was not required in any of the patients

neither was surgical re-exploration needed for infection or other complications. However in two patients superficial wound redness was noted when suture removal was done, this improved with oral Augmentin (amoxicillin and potassium clavulanic acid) 1 gm. twice a day for 5 days. We did not have a single case of deep (organ/space) infection in the series.

## DISCUSSION

In one study, the rate of infection in diabetics was not statistically different from the non-diabetics<sup>25</sup>. The strength of this study includes the diversity of patient population and the fact that every patient had a proven electro-physiological diagnosis. A possible potential limitation of this study is that the study sample may not be too big and for the fact that the study was not stratified by endoscopic versus the open release, which in any case was not the objective of the study.

With respect to the antibiotic efficacy, the antibiotic prophylaxis protocol employed in the study has shown that the approach is safe and efficacious, assuming that an infection rate of less than 1% is considered as acceptable for CTR surgery<sup>4</sup>. Injudicious and the prolonged use of postoperative antibiotics does not significantly bring down the infection rate and its unwarranted prolonged use can expose the patient to more adverse drug effects, hence increasing the probability of infections by antibiotic-resistant bacteria and inhibiting normalisation of body temperature. It may also elevate the CRP levels prolonging the duration of hospital stay and increasing the overall medical cost<sup>26</sup>.

The assessment checked on the results for patients who experienced just CTR. Further roads of study may incorporate exploring the pace of patients experiencing other delicate tissue techniques of the hand and wrist that do not require preoperative anti-infection agents, including trigger finger discharges and first dorsal compartment discharges. By and by, this examination speaks to the primary examination concerning auxiliary to delicate tissue techniques of the hand. Despite the fact that the utilization of prophylaxis must be considered concerning the hazard profile of every individual patient, routine prophylactic antibiotics may not be demonstrated in CTR.

## CONCLUSION

Single dose antibiotic is best suited for patients with CTS. Infection rate in CTR surgery cases is low. Furthermore, unilateral involvement was more common than bilateral involvement in the study. In addition, handedness definitely had a role to play in unilaterality. Thus, for the patients the prime motive to undergo surgery was the troublesome

symptoms of pain and paresthesia.

### ACKNOWLEDGEMENTS

The author acknowledged the Dammam Medical Complex - Saudi Arabia for facilitating the research study.

### CONFLICT OF INTEREST

The author declares no conflict of interest.

### ETHICS APPROVAL

The study has been approved by the Department of Neurosurgery, Dammam Medical Complex - Saudi Arabia.

### PATIENTS CONSENT

The written consent has been obtained from the patients of the research study.

### AUTHOR'S CONTRIBUTION

The author is fully contributed in the critical write-up of this research.

### REFERENCES

1. Michelsen H, Posner MA. Medical history of carpal tunnel syndrome. *Hand Clin.* 2002;18:257-268.
2. Patterson J, Simmons BP. Outcome assessment of carpal tunnel syndrome. *Hand Clin.* 2002;18:359-363.
3. Harness NG, Inacio MC, Pfeil FF, Paxton LW. Rate of infection after carpal tunnel release surgery and effect of antibiotic prophylaxis. *J Hand Surg Am.* 2010; 35(2):189-196.
4. Burton C, Chesterton LS, Davenport G. Diagnosing and managing carpal tunnel syndrome in primary care. *Br J Gen Pract.* 2014;64(622):262-3.
5. Amir S, Qadir M, Usman M. Clinical profile of patients with carpal tunnel syndrome. *Khyber Med Uni J.* 2018;10(1).
6. Szabo RM, Steinberg D. Nerve entrapment syndromes in the wrist. *J Am Acad Orthop Surg.* 1994;2:115-123.
7. de Azevedo JW, de Oliveira AB, Nascimento Vd, de Paiva HR Jr, Viegali L, Rocha MA. Profile of patients on sick leave with carpal tunnel syndrome. *Acta Ortop Bras.* 2015;23(5):244-6.
8. Awan AS, Khan A, Afridi SA, Khan IU, Bhatti SN, Ahmed E, et al. Early response of local steroid injection versus mini incision technique in treatment of carpal tunnel syndrome. *J Ayub Med Coll Abbottabad.* 2015;27(1):192-6.
9. Piazzini DB, Aprile I, Ferrara PE, Bertolini C, Tonali P, Maggi L, et al. A systemic review of conservative treatment of carpal tunnel syndrome. *Clin Rehab.* 2004; 21(4): 299-314.
10. Clinical practice guidelines on the treatment of carpal tunnel syndrome (PDF). American Academy of Orthopaedic Surgeons. 2008.
11. Adams ML, Franklin GM, Barnhart S. Outcome of carpal tunnel surgery in Washington State worker's compensation. *Am J Int Med.* 1994; 25:527-536.
12. Das S, Brown MG. In search of complications in carpal tunnel decompression. *Hand.* 1976;8:243-249.
13. Kleinert J, Hoffman J, Crain G, Larsen C, Goldsmith L, Firelli J. Postoperative infection in a double-occupancy operating room: A prospective study of two thousand four hundred and fifty-eight procedures on the extremities. *J Bone Joint Surg.* 1997; 79A:503-513.
14. Rizvi M, Bille B, Holtom P, Schnall S. The role of prophylactic antibiotics in elective hand surgery. *J Hand Surg.* 2008; 33A:413-420.
15. Hanssen A, Amadio P, Desilva S, Ilstrup D. Deep postoperative wound infection after carpal tunnel release. *J Hand Surg.* 1989; 14A:869-873.
16. Stevens JC, Smith BE, Weaver AL, Bosch EP, Deen HG, Wilkens JA. Symptoms of 100 patients with electromyographically verified carpal tunnel syndrome. *Muscle Nerve.* 1999;22(10):1448-56.
17. Kasundra GM, Sood I, Bhargava AN, Bhushan B, Rana K, Jangid H, Shubhakaran K, Pujar GS. Analyzing efficacy and utility of clinical tests and various diagnostic modalities. *J Neurosci Rural Pract.* 2015; 6(4):504.
18. Aroori S, Spence RA. Carpal tunnel syndrome. *Ulster Medical J.* 2008;77(1):6-17.
19. Mangram AJ, Horan TC, Pearson ML, Silver LC, Jarvis WR. The hospital infection control practices advisory committee. Guidelines for prevention of surgical site infection. *Am J Infect Control.* 1999; 27:97-134.
20. ASHP therapeutic guidelines on antimicrobial prophylaxis in surgery. American society of health-system pharmacists. *Am J Health Syst Pharm.* 1999; 56(18):1839-88.
21. Mastronardi L, Tatta C. intraoperative antibiotic prophylaxis in clean spinal surgery: a retrospective analysis in a consecutive series of 973 cases. *Surg Neurol.* 2004; 61(2):129-35.
22. Classen DC, Evans RS, Pestotnik SL, Horn SD, Menlove RL, Burke JP. The timing of prophylactic administration of antibiotics and the risk of surgical wound infection. *N Engl J Med.* 1992;326(5):281-6.
23. Shapiro S. Microsurgical carpal tunnel release. *Neurosurg.* 1995. 37: 66-70.
24. Bahrmann A1, Zieschang T, Neumann T, Hein G, Oster P. Carpal tunnel syndrome in diabetes mellitus. *Med Klin (Munich).* 2010; 105(3):150-4.
25. Harness NG, Inacio MC, Pfeil FF, Paxton LW. Rate of infection after carpal tunnel release surgery and effect of antibiotic prophylaxis. *J Hand Surg Am.* 2010; 35(2):189-96.
26. Ohtori S, Inoue G, Koshi T, Yamashita M, Yamauchi K, Suzuki M, et al. Long-term intravenous administration of antibiotics for lumbar spinal surgery prolongs the duration of hospital stay and time to normalize body temperature after surgery. *Spine.* 2008;33(26):2935-7.