

Accuracy of High Resolution Ultrasound Examination for Prediction of Malignancy Thyroid nodules: FNAC or HP as reference standards

Waseem Mehmood Nizamani¹, Asha Naresh Sairani², Aneel Kumar Vaswani³, Bheesham Kumar Shahani⁴

ABSTRACT

Background: Thyroid nodules comprise a diagnostic challenge mainly because of the need to exclude thyroid malignancy. Approximately, 4% is an estimated prevalence of thyroid nodule on palpation with 15% lifetime risk of developing a thyroid nodule.

Objective: To provide importance of sonographic and doppler criteria for differentiation between benign and malignant solid thyroid nodules and their correlation with Fine-needle aspiration cytology (FNAC) or histopathology (HP).

Methods: A prospective study of 103 patients (January 2012 to June 2013) selected from radiology department of Dr.Ziauddin Hospital Karachi who came for ultrasound (US) of thyroid with clinical diagnosis of thyroid nodule followed by FNAC. Presence of malignant features were taken as positive finding for malignancy. The results of US were compared with FNAC/HP and diagnostic accuracy was calculated.

Results: Out of 103 cases, 80 were labeled as true positive because US and FNAC results were positive for malignancy while the 2 were false positive as US shows malignant features but FNAC results were negative. 8 patients were labeled as true negative because US and FNAC were negative for malignancy and 13 patients were false negative because US results were negative for malignancy but FNA results were positive. The overall sensitivity and specificity of US was 86.0% and 80.0% respectively. Similarly the positive predictive value (PPV) was 97.5%, negative predictive (NPV) was 38.0% and diagnostic accuracy was 85.43% when compared with FNAC/HP results.

¹ **Waseem Mehmood Nizamani**

Senior Registrar, Department of Radiology, Ziauddin University and Hospitals, Karachi.

² **Asha Naresh Sairani**

Department of Radiology, Ziauddin University and Hospitals, Karachi.

³ **Aneel Kumal Vasvani**

Department of Radiology, Ziauddin University and Hospitals, Karachi.

⁴ **Bheesham Kumar Shahani**

Department of Radiology, Ziauddin University and Hospitals, Karachi.

Corresponding Author

Waseem Mehmood Nizamani

Conclusion: Although US is an important tool for prediction of thyroid nodule malignancy, it cannot substitute FNAC/HP for accurate detection for malignancy. However, it can reliably anticipate the suspicion lesions which need intervention on priority basis.

KEY WORDS: *Fine-needle Aspiration Cytology, Nodule, Thyroid, Ultrasound.*

Cite as: *Nizamani WM, Sairani AS, Waswani AK, Shahani BK. Accuracy of high resolution ultrasound examination for prediction of malignancy thyroid nodules. Pak J Med Dent 2015; 4(1):28-34.*

INTRODUCTION

Risk factors that increase the likelihood of malignancy of a thyroid nodule are age under 30 or over 60 years, male sex (8% versus 4% in female), history of head and neck irradiation in childhood and family history of medullary thyroid carcinoma (MTC) or multiple endocrine neoplasia (MEN) type 2.¹¹ The prevalence of thyroid nodules on US is 13% to 67%. Fortunately, less than 7% of thyroid nodules are malignant.² Long-standing goiter (more than 5 years) is considered as the one of the strongest risk factor for the development of thyroid malignancy.³ Therefore, in order to diagnose thyroid cancers early on, but spare other patients from the risks of unnecessary fine needle aspirations, it is essential to have a strategy to determine which nodules should undergo FNAC.⁴

Imaging modality of choice for the investigation of thyroid nodules is high resolution US.^{2,5} As compared with FNAC, thyroid US has the advantage of being a noninvasive procedure and giving immediate information. Among several US patterns, hypoechogenicity of the nodule, spot microcalcifications, and the absence of halo sign have been useful for predicting thyroid malignancy.⁵ US is frequently misperceived as unhelpful for identifying features that distinguish benign from malignant nodules. Microcalcifications are one of the most specific US findings of a thyroid malignancy.⁷ Some author found an 18.5% prevalence of malignancy among thyroid nodules with peripheral calcification.¹⁰ From the above described US patterns, the presence of at least

one malignant US finding had a sensitivity of 83.3%, a specificity of 74.0%, and a diagnostic accuracy of 78.0%.⁸ Use of FNAC has led to a considerable decrease in the number of surgical excisions and to a twofold increase in the diagnosis of carcinoma.⁶ The sensitivity and specificity of FNAC are 95% & 90% respectively when compared with histopathological results of thyroid nodule.⁹

Elastography is a newly developed dynamic technique but its less easily available than conventional ultrasound. Other modalities for the assessment of thyroid nodules are thyroid scintigraphy, CT scan and MRI but US is the preferred modality due to its easy availability, cost effectiveness specially in developing countries like Pakistan, lack of ionizing radiation and its higher sensitivity for predicting malignant features of thyroid nodules. US is also helpful in predicting patients that need urgent invasive diagnostic workup i.e., FNAC or excisional biopsy but spare other patients from risks of unnecessary FNAC and surgical intervention.⁵⁻¹⁰ By conducting this study many patients can forgo from unnecessary invasive diagnostic workup and their complications. This study is also helpful in screening those patients who need urgent diagnostic or surgical management; hence with this method mortality and morbidity associated with thyroid malignancy can be reduced by giving them early and immediate treatment when the disease process is less aggressive in their early phase.

METHODOLOGY

A prospective study of 103 patients between January 2012 to June 2013 that came to radiology department of Dr.Ziauddin Hospital

Karachi Pakistan for ultrasound of thyroid with clinical diagnosis of thyroid nodule followed by FNAC or diagnosed as having thyroid nodule on thyroid scan and came for Fine-needle aspiration under ultrasound guidance. This was a cross-sectional, validation study. The sampling technique used was non-probability, purposive type.

Informed consent was taken from all the patients and approval of the ethical committee was taken before the study. Inclusion criteria of this study was all the patients that have diagnosed as having suspicious thyroid nodules on clinical examination (hard palpable thyroid nodule, rapidly enlarging thyroid lesion or thyroid nodule associated with hoarseness of voice) or thyroid scan (cold nodule) referred for FNAC of the lesion under ultrasound guidance or have undergone excisional biopsy after inconclusive or suspicion FNAC results. Patients that are already diagnosed as having malignant thyroid lesions on histopathology or those who have not undergone FNAC or excisional biopsy are excluded from this study.

Ultrasound of thyroid gland was performed with high resolution linear array transducer/probe (at least 7.5 MHz) on Toshiba Xario™200 in the real time mode by an experienced radiologist. Doppler Duplex of all the nodules was also performed. Static hard copy images of the lesion were obtained with high quality printer for documentation. All the details were recorded in the proforma for the purpose of study. Evaluation of malignant thyroid nodule was performed. Presence of 1 or more malignant features (microcalcifications, irregular margins, marked hypoechogenicity, taller than wider shape, predominantly solid composition and presence of intranodular color flow) was taken as positive finding for malignant nodule and absence of all malignant features was taken as negative.

Then all the patients underwent FNAC or if necessary excisional biopsy for HP analysis in cases if the results of FNAC were in-conclusive or suspicious. The results of ultrasound were compared with cytology or histopathology findings and diagnostic accuracy was calculated.

The statistical analysis was done using SPSS software (IBM SPSS statistics v 22; SPSS, Inc, Chicago, IL). Descriptive analysis was conducted i.e., frequencies and percentages for

categorical variables like gender, mean and standard deviation for the continuous variables like age. Frequencies were calculated in terms of presence or absence of malignant features in thyroid nodules on real time ultrasound and Doppler ultrasound out of total cases. *p* value of equal to or less than 0.05 was considered significant. Sensitivity, Specificity, Negative and Positive predictive values were determined by taking FNAC or HP analysis as reference standard.

RESULTS

One hundred and three patients who fulfilled our criteria were included in the study. There were 34 (33.00 %) males and 69 (66.99 %) females. (Figure 1) The age of these patients ranged between 20 years and 60 years. The mean age was 46 years. Mean ages in male and female patients were not significantly different.

Out of 103, 82 patients showed at least one malignant feature in their thyroid nodules and were taken as positive. Majority nodules i.e., 73 (89.0%) were solid on US and 35 (42.68%) nodules appears as hypoechoic. 15 (18.29%) nodules shows microcalcifications and 45 (54.87%) nodules shows intranodular vascularity on color Doppler. In 42 (51.21%) nodules US showed irregular borders (Figure 2 and Table 1).

From those 82 US positive patients, 80 (97.56%) were true positive because FNAC shows malignant cells in them, while 2 (2.43%) were false positive because FNAC results showed benign pathology. 8 patients were labeled as true negative as US fails to show any malignant features and subsequent FNAC results showed benign pathology. In 13 patients US showed none of the malignant features rather it showed benign features such as comet tail sign, coarse calcification, more than 50% cystic component, but FNAC results were positive for malignancy hence these were false negative.

The overall sensitivity and specificity of US was 86.0 % and 80.0% respectively. Similarly the PPV was 97.5%, NPV was 38.0% and diagnostic accuracy was 85.43% when compared with FNAC/HP results (Figure 3).

Table 1: Table showing numbers and percentages of malignant features detected in positive nodules on US.

Sonographic Characteristics	Number of Nodules	Percentages
Solid appearance	73	89.00%
Hypochoic texture	35	42.68%
Microcalcification	15	18.29%
Intranodular color flow	45	54.87%
Irregular borders	42	51.21%

Table 2: Table showing comparison of results (Sensitivities and specificities) of the with other similar studies performed at different setups.

Comparison	SEN	SPEC	DA
Current Study	86.0%	80.0%	85.43%
Moon WJ et al (2008)	83.3%	74.0%	78.0%
Yunus M et al (2010)	92.0%	77.3%	80.7%
Rago T et al (2007)	81.0%	62.0%	-
Papini E et al (2002)	77.5%	85.0%	-

* SEN: Sensitivity
 * SPEC: Specificity
 * DA: Diagnostic Accuracy

Figure 1: Pie-chart showing ratio of males and females included in the study.

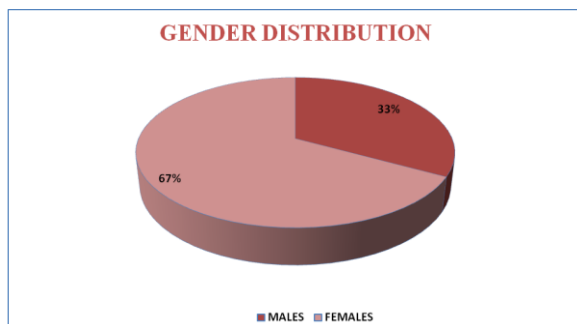


Figure 2: Bar-chart showing percentages of malignant US features detected in the thyroid nodules of patients included in the study.

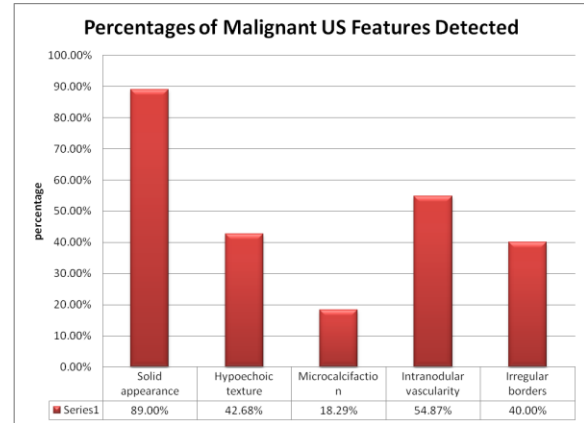
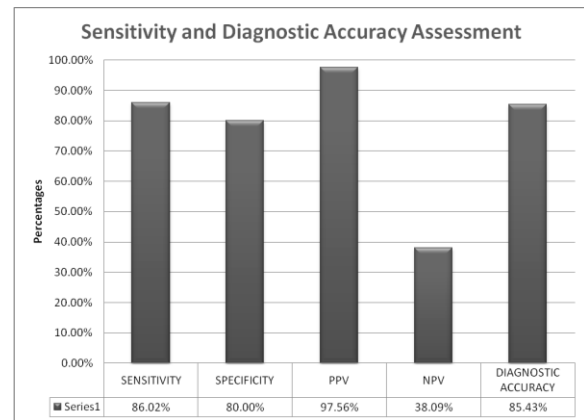


Figure 3: Bar-chart showing results of the study including sensitivity, specificity, positive predictive value (PPV), negative predictive value (NPV) and diagnostic accuracy



DISCUSSION

Thyroid nodules are frequently encountered clinical problems in routine practice. The prevalence of palpable thyroid nodules in iodine-sufficient areas is 5% and 1% in women and men respectively. Contrarily, high-resolution US can detect thyroid nodules in 19–67% of randomly selected individuals with higher frequencies in women and the elderly. The clinical importance of thyroid nodules based on possibility of thyroid cancer which occurs in 5–15% depending on age, sex, radiation exposure history, family history, and other factors.¹¹⁻¹⁶

Our study is the prospective study of 103 patients between January 2012 to June 2013 that came to radiology department of Dr.Ziauddin Hospital Karachi Pakistan for US of thyroid with clinical diagnosis of thyroid nodule followed by FNAC or diagnosed as having cold thyroid nodule on thyroid scan and came for Fine-needle aspiration under ultrasound guidance. Ultrasound examination of the thyroid gland using graded compression technique using high resolution, high frequency probes (linear array 7.5- 10MHz and curvilinear array 3.5-7.0MHz). FNAC has been done to detect malignancy in thyroid nodule.

The purpose of conducting this study was to avoid extensive and expensive diagnostic modalities in most patients with benign disease without omitting the minority of patients who have thyroid malignancy. Several studies have been done to establish the ability of US to differentiate benign from malignant thyroid nodules and their results compared with FNAC, thyroid US has the advantage of being a non-invasive procedure and giving instant information.¹⁷

It is not reasonable to biopsy every thyroid nodule discovered with US. Reasons for limiting thyroid biopsy, include the small percentage of malignant lesions, the small number of cases of thyroid cancer in which early diagnosis may actually have an influence, the economic and community costs, the strain on radiology resources, and the patient uncertainty and anxiety incumbent on a potentially malignant diagnosis. Hence, reliable guidelines for nodules that may not require biopsy have become essential.¹⁸

In the study various ultrasound criteria were assessed including microcalcifications, marked hypoechogenicity, tall shape, irregular margins and intranodular pattern of color flow in predicting malignant nature of these lesions. Out of 103, 82 nodules were labeled as positive. 73 (89.0%) were solid, 35 (42.68%) nodules shows hypoechoic texture, 15 (18.29%) nodules shows microcalcifications, 45 (54.87%) nodules shows intranodular vascularity and 42 (51.21%) nodules showed irregular borders. (Table 1) In the current study the sensitivity and specificity of US for the prediction of malignancy in thyroid nodule was 86.0% and 80.0% respectively and

diagnostic accuracy was 85.43% when compared with FNAC/HP results.

In 2008 Moon WJ [8] and its co-workers compared sonography with FNAC/surgical findings of 831 patients having 849 nodules on US. They concluded that no single US feature suggestive of malignancy had an overall diagnostic accuracy that exceeded 75.0%. However, the overall sensitivity, specificity and diagnostic accuracy of US for diagnosis of malignancy was 83.3%, 74.0% and 78.0% respectively. (Table 2 and figure 4-5)

Similarly Yunus M et al² in 2010 found that the sonographic classification method resulted in a sensitivity of 92%, specificity of 77.3%, PPV of 65.7%, NPV of 95.3% and accuracy of 80.7%. They found that predominantly central color flow pattern in solid nodules has highest sensitivity malignancy (84%) and markedly hypoechoic solid nodule reaches the highest specificity for malignancy (94%). (Table 2 and Figure 4-5)

Rago T and its fellows compared the results of US elastography with FNAC in 2007 and concluded that US elastography has highest sensitivity and specificity reaching 100% for prediction of malignancy in thyroid nodule as compared to conventional US which has sensitivity and specificity of 81% and 62% respectively. (Table 2 and Figure 4)

One group of researchers (Papini E et al) concluded in 2002 that the presence of microcalcifications presented a higher specificity for malignancy (95%) than the findings of irregular margins (85%) or intranodular vascular images (80.8%), but the predictive value of microcalcifications was blunted by their low sensitivity (29.0% vs. 77.5% and 74.2%, respectively).¹⁹ (Table 2 and Figure 4)

In the current study no single malignant US feature to have highest sensitivity or specificity for the prediction of malignancy in thyroid nodule, however, combination of 1 or more features have shown significance for the suggestion of malignancy.

Figure 4: Bar chart showing comparison of sensitivities and specificities of US for the predication of malignancy in the thyroid nodules for the current and previous studies.

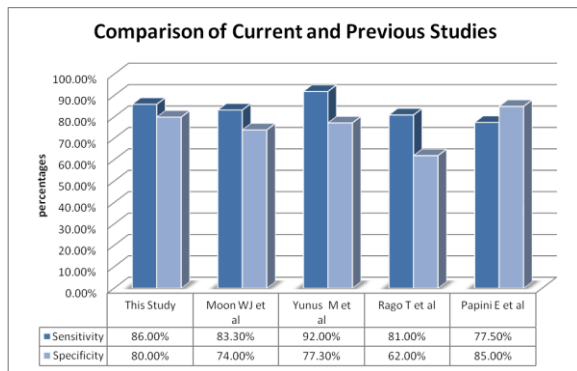
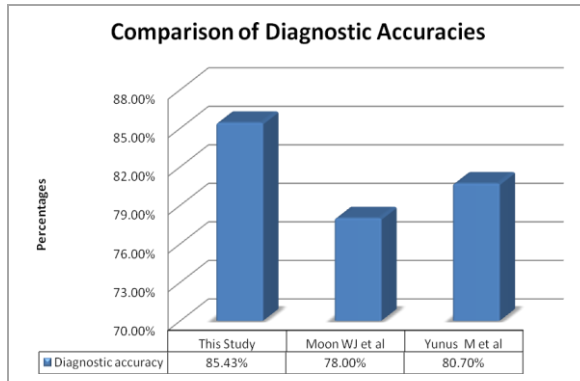


Figure 5: Bar chart showing comparison of diagnostic accuracies of US for the predication of malignancy in the thyroid nodules for the current and previous studies.



CONCLUSION

US is an important baseline tool for prediction of malignancy in thyroid nodule. By stratifying malignant from benign lesions, suspicion lesions that need intervention or treatment on priority/urgent basis can be anticipated. Similarly by pointing out benign lesions it is possible to prevent unnecessary invasive procedures like surgery or excisional biopsy, however, it cannot substitute FNAC/HP for accurate diagnosis for malignancy. It should be utilized as a routine screening method in patients with thyroid nodule.

REFERENCES

¹ Polyzos SA, Kita M, Avramidis A. Thyroid nodules - stepwise diagnosis and management. *Hormones (Athens)*. 2007 Apr-Jun;6(2):101-119.

² Yunus M, Ahmed Z. Significance of ultrasound features in predicting malignant solid thyroid nodules: need for fine-needle aspiration. *J Pak Med Assoc*. 2010 Oct;60(10):848-853.

³ Sushel C, Khanzada TW, Zulfiqar I, Samad A. Histopathological patterns of diagnosis in patients undergoing thyroid operations. *Rawal Med J*. 2009;34:14-6.

⁴ Liu YI, Kamaya A, Desser TS, Rubin DL. A bayesian classifier for differentiating benign versus malignant thyroid nodules using sonographic features. *AMIA Annu Symp Proc*. 2008; 2008: 419-423

⁵ Rago T, Santini F, Scutari M, Pinchera A, Vitti P. Elastography: new development in ultrasound for predicted malignancy in thyroid nodules. *J Clin Endocrinol Metab*. 2007;92:2917-2922.

⁶ Bonavita JA, Mayo J, Babb J, Bennett G, Oweity T, Macari M, Yee J. Pattern recognition of benign nodules at ultrasound of the thyroid: which nodules can be left alone? *AJR Am J Roentgenol*. 2009 Jul;193(1):207-213

⁷ Hoang JK, Lee WK, Lee M, Johnson D, Farrell S. US features of thyroid malignancy: pearls and pitfalls. *Radiographics*. 2007 May-Jun;27(3):847-60; discussion 861-865

⁸ Moon WJ, Jung SL, Lee JH, Na DG, Baek JH, Lee YH et al. For the thyroid study group, Korean Society of Neuro- and Head and Neck Radiology. Benign and malignant thyroid nodules: US differentiation--multicenter retrospective study. *Radiology*. 2008 Jun;247(3):762-770.

⁹ Smadi AA, Ajarmeh K, Wreikat F. Fine-Needle Aspiration of Thyroid Nodules has high sensitivity and specificity. *RMJ*. 2008; 33(2): 221-224.

¹⁰ Yoon DY, Lee JW, Chang SK, Choi CS, Yun EJ, Seo YL, et al. Peripheral calcification in thyroid nodule. Ultrasonographic feature and prediction of malignant. *J Ultrasound Med*. 2007 Oct;26(10):1349-1355.

¹¹ Cooper DS, Doherty GM, Haugen BR, Kloos RT, Lee SL, Mandel SJ et al. American Thyroid Association (ATA) Guidelines Taskforce on Thyroid Nodules and Differentiated Thyroid Cancer. Revised American Thyroid Association management guidelines for patients with thyroid nodules and differentiated thyroid cancer. *Thyroid*. 2009 Nov;19(11):1167-1214.

¹² Tunbridge WM, Evered DC, Hall R, Appleton D, Brewis M, Clark F et al. The spectrum of thyroid disease in a community: the Wickham survey. *Clin Endocrinol (Oxf)*. 1977 Dec;7(6):481-493.

¹³ Vander JB, Gaston EA, Dawber TR. The significance of nontoxic thyroid nodules. Final report of a 15-year study of the incidence of thyroid malignancy. *Ann Intern Med*. 1968 Sep;69(3):537-540.

¹⁴ Tan GH, Gharib H. Thyroid incidentalomas: management approaches to nonpalpable nodules discovered incidentally on thyroid imaging. *Ann Intern Med.* 1997 Feb 1;126(3):226-231.

¹⁵ Hegedüs L. Clinical practice. The thyroid nodule. *N Engl J Med.* 2004 Oct 21;351(17):1764-1771.

¹⁶ Mandel SJ. A 64-year-old woman with a thyroid nodule. *JAMA.* 2004 Dec 1;292(21):2632-2642.

¹⁷ Shetty SK, Maher MM, Peter FH, Halpern EF, Aquino SL. Significance of incidental thyroid lesions detected on CT: Correlation among C.T, sonography and pathology. *Am J Roentgenol* 2006; 187: 1349-1356.

¹⁸ Bonavita JA, Mayo J, Babb J, Bennett G, Oweity T, Macari M, Yee J. Pattern recognition of benign nodules at ultrasound of the thyroid: which nodules can be left alone? *AJR Am J Roentgenol.* 2009 Jul;193(1):207-213.

¹⁹ Papini E, Guglielmi R, Bianchini A, Crescenzi A, Taccogna S, Nardi F et al. Risk of malignancy in nonpalpable thyroid nodules: predictive value of ultrasound and color-Doppler features. *J Clin Endocrinol Metab.* 2002 May;87(5):1941-1946.